

Integrating the Healthcare Enterprise



5

IHE Cardiology (CARD) White Paper

10

3D/4D Echocardiography Workflow

15

Date: August 5, 2011

20 Author: IHE Cardiology Technical Committee

Email: cardio@ihe.net

CONTENTS

25	Overview.....	3
	Abstract.....	3
	Open Issues and Questions	3
	Closed Issues.....	4
30	1 Introduction.....	6
	1.1 Problem Statement.....	6
	1.2 Scope	6
	1.3 Definitions	6
	1.4 References	7
35	2 Use cases.....	8
	2.1 Workflow use cases.....	8
	2.1.1 3D Echo workflow within the enterprise.....	8
	2.1.2 3D Echo Image exchange via Media	10
	2.2 Review/Display use cases.....	11
40	2.2.1 3D quantification	11
	2.2.2 Visualization and analysis of valvular anatomy	13
	2.2.3 Visualization and analysis of congenital heart defects	15
	2.2.4 3D Fetal Echocardiography	17
	2.2.5 Volume Stress Echo.....	19
45	2.2.6 Tissue Doppler Imaging Use Case.....	21
	2.3 Use cases for future consideration.....	22
	3 Technical Requirements /Pre-Requisites from DICOM.....	23
	3.1 nD Presentation State requirements.....	23
	3.2 Structured Report Requirements	24
50	4 Proposal for the 3D/4D Echo Supplement.....	25

55

Overview

3D Echocardiography is gaining more importance in clinical routine. However until recently there was no standard for the storage and exchange of these volume data. Each vendor developed a proprietary way to store their volumes data, not allowing for exchange with and review on other vendor workstations. At the end of 2008 DICOM approved Supplement 43 (Enhanced US Volume storage IOD) to address the need of exchanging 3D/4D ultrasound datasets between different vendors. IHE Cardiology decided to further improve inter-operability and to encourage implementation of this new SOP class by defining a 3D/4D Echocardiography workflow. Due to the lack of storing derived views and their geometric transformation in DICOM, it was decided to first provide a white paper to define the clinical use cases as a basis for a profile development in a subsequent year.

Abstract

The use of three dimensional (3D) echocardiography imaging in clinical practice is still relatively new; as a result, there are major changes in the way these studies are reviewed compared to studies of 2D images. Therefore this whitepaper details clinical use cases on the acquisition, exchange and review of 3D ultrasound data sets.

Open Issues and Questions

75

#	Issue/Answer
1.	<p>Should two step loading of volume data be described in these use cases?</p> <p>On some systems loading of volume data sets might be slow due to the size of the data sets. Should it be part of the use cases, that together with each derived view a regular 2D ultrasound clip should be stored as well? When opening that view, the user could initially review the 2D ultrasound clip and only load, open the volume data, if he wants to do some further manipulations.</p> <p>Response: Yes, in many instances the processed 3D image may be sufficient.</p>
2.	<p>Are there any specific 3D measurements that do not have a 2D equivalent?</p> <p>Currently, for most of the measurements done on volume data sets, there is a 2D equivalent, which is done based on some geometric assumptions (e.g. calculation of ejection fraction based on Teichholz equation, Simpson’s rule, or area length method). However are there measurements that do not have a 2D equivalent? If so, which are these?</p>

#	Issue/Answer
	Response: Even though we are currently not aware of any additional measurements, Perhaps as 3D becomes more prevalent some measurements exclusive to 3D may be developed.
3.	<p>What would be the advantage of doing Tissue Doppler on volume data sets rather than in 2D?</p> <p>A description of the Tissue Doppler Imaging use case is needed in order to stress the advantages of volume acquisition/review.</p> <p>Response: Theoretically there may be clinically relevant information regarding left ventricular systolic and diastolic function from 3D Tissue Doppler. Such information may have clinical consequences including pharmacologic therapy and timing of valve replacement. Further studies will be necessary.</p>
4.	<p>For 3D measurements, should there be a reference in the DICOM structured reports to the images and area, the measurements were done on?</p> <p>Currently in 2D, most Echocardiography SRs do not contain any reference in the SRs to the image/frame/region the measurement was taken on. Does this change with 3D?</p> <p>Response: Not necessary.</p>

Closed Issues

#	Issue/Answer
1.	<p>Are there any use cases for image fusion with CT/MR?</p> <p>Response:</p> <p>This is an interesting topic. Currently there are no use case for image fusion with other modalities, also due to the lack of having a fixed coordinate system and reference points. However there is some interest in fusing echo data with CT in order to get a better assessment of the morphology. Furthermore it would be of interest to overlay EP data on top of Echo images.</p> <p>Since there is no complete understanding of these use cases yet, these scenarios will be listed in a section for future use cases.</p>
2.	<p>Are there any use cases for using Maximum/Minimum Intensity Projections</p> <p>Response: No</p>
3.	<p>Are there any use cases, in which it would be helpful to time limit clips for display purposes?</p>

#	Issue/Answer
	<p>Response:</p> <p>This would be very useful in stress echo. After acquiring multiple beats per stage, the most representative beat can be select. If atrial or ventricular premature beats occur, they can be omitted from function analysis.</p> <p>This functionality will be addressed in the Volume Stress Echo use case.</p>
4.	<p>Are 3D visualization of the interior of a ventricle clinically useful</p> <p>Response:</p> <p>Such 3D rendered views of volumes are useful for depicting regional motion abnormalities not only due to ischemic changes but also for structural abnormalities and how they change throughout the cardiac cycle. This could also be of use to define changes in shapes and curvatures not apparent by 2D images alone. Also the 3D casts of Doppler flow areas across valves or holes for example would prove very useful.</p> <p>This functionality will be addressed in the 3D quantification use case.</p>

80 **1 Introduction**

1.1 Problem Statement

3D Echocardiography is gaining more importance in clinical practice due to more accurate and reliable quantification, better reproducibility, and new views on valvular and congenital heart disease for improved diagnostics and pre-operative planning. However until recently there was no standard for the storage and exchange of these volume data. Each vendor developed a proprietary way to store their volume data, not allowing for exchange with, and review on, other vendor workstations. At the end of 2008 DICOM approved Supplement 43 (Enhanced US Volume storage IOD) to address the need of exchanging 3D/4D ultrasound datasets between different vendors. IHE Cardiology decided to further improve interoperability and to encourage implementation of this new SOP class by defining a 3D/4D Echocardiography workflow.

After discussing this approach with clinical representatives it turned out, that in order to define a meaningful clinical workflow, it would be essential to not only address the storage of the volumes but also the review and manipulation of these volume objects. In this context it is important to also address the hand off between sonographer and cardiologist, which requires not only the volume data but also some information as to how certain views have been generated, so that the cardiologist can seamlessly continue the work of the sonographer. In DICOM terms this would require an n-dimensional (nD) Presentation State, which is currently under development by DICOM WG11. Since finalization of the corresponding work item will take some more time, it was decided to start development of this profile by defining clinical use cases for 3D Echo during year 6 and to use the results for a profile in a subsequent year.

1.2 Scope

In the context of this whitepaper we will be focusing on interactions between the sonographer at the scanner and the reading physician at a review workstation. The overall clinical workflow (including patient admission, ordering, scheduling, image acquisition, storage and reporting) is covered in the Echo Workflow Profile and will be most likely the same for 3D/4D Echo workflow, since all studies will include both 2D and 3D objects. The critical part for 3D/4D workflow is on the review of the 3D/4D datasets and the interaction with the volume data.

1.3 Definitions

B-Mode	In B-mode ultrasound, a linear array of transducers simultaneously scans a plane through the body that can be viewed as a two-dimensional image on screen
CW	Continuous Wave Doppler: It involves continuous generation of ultrasound waves coupled with continuous ultrasound reception. Doppler information is sampled along a line through the body, and all velocities detected at each time point is presented (on a time line)

IOD	Information Object Definition
MPR	Multi-planar reconstruction: MPR is a two-dimensional reformatted image that is reconstructed in arbitrary planes from a stack of axial image data
PISA	Proximal Iso-velocity Surface Area. PISA is based on the hemodynamic principles of flow through a small circular orifice in a flat plate.
Presentation State	DICOM object which contains display information for a given image (set of images) like region of interest, annotations, geometrical transformations, contrast or color setting, ...
PW	Pulsed Wave Doppler. It uses a transducer that alternates transmission and reception of ultrasound. Doppler information is sampled along a line through the body, and all velocities detected at each time point is presented (on a time line)
SR	DICOM Structured Report
TDI	Tissue Doppler Imaging (TDI) is an ultrasound technique that enables the quantification of regional myocardial function by measuring myocardial velocities

1.4 References

- 110 [1] Three-Dimensional Echocardiography: The Benefits of the Additional Dimension. Roberto M. Lang, Victor Mor-Avi, Lissa Sugeng, Petra S. Nieman, David J. Sahn. Journal of the American College of Cardiology, Vol. 48, No. 10, 2006
- [2] ASE Position Paper. Three-Dimensional Echocardiography: A Review of the Current Status and Future Directions. Judy Hung, Roberto Lang, Frank Flachskampf, Stanton K. Shernan, Marti L. McCulloch, David B. Adams, James Thomas, Mani Vannan, and Thomas Ryan. Journal of the American Society of Echocardiography, March 2007
- 115 [3] IHE Cardiology Technical Framework, Volume 1, Revision 3.0 (http://www.ihe.net/Technical_Framework/upload/IHE_CARD_TF_Rev3-0_Vol1_2010-10-15.pdf)

120 **2 Use cases**

Use cases defined in this document will focus on two different aspects of 3D Echocardiography. The first group of use cases addresses general workflow issues, like the generation, storage and exchange of volume data either through network transfer or via external media. These use cases will be the basis for interoperability requirements. The second group of use cases deals with the review of volume datasets and addresses display of, and interaction with, volume data, especially the handoff between different parties involved in generation and review. These use cases will be used to derive requirements for an nD presentation state.

2.1 Workflow use cases

2.1.1 3D Echo workflow within the enterprise

130 **Description**

This use case describes the workflow in the echo lab, including image acquisition, storage, retrieval and review of a study. Image acquisition and review includes both 2D as well as 3D acquisitions. For details on patient administration, ordering and scheduling please refer to section 4 in [3].

135 **Scenario**

Dr. Winter works in an echo lab with three different ultrasound systems, all from different vendors (A, B, C). All of the scanners support 3D echocardiography and store volume data sets in a standardized, vendor neutral format (DICOM enhanced US Image object) as well as n-dimensional presentation states containing specific display information, which would allow the storage of representative views of the volume data set. Furthermore the lab uses a PACS from vendor D and a review workstation from one of the scanner vendors (A). Both the PACS and the workstation support the storage and display of the volumes and presentation states stored in a standardized format. Furthermore there are three sonographers employed in the echo lab as well, who perform the image acquisition (2D and 3D), generate some representative views and perform some measurements.

Tony Smith presents at Dr. Winter's Echo Lab because of acute chest pain, shortness of breath and fatigue. One of the Sonographers performs an echocardiogram on the Echo System from vendor B. The study includes 3D views of the aortic valve and some measurements performed on those images. She stores the images to their PACS. Later on, Dr. Winter retrieves the study from PACS and reviews it on his workstation. He opens the derived views, further manipulates the volume, and arrives at the diagnosis of severe Aortic Regurgitation.

Pre-Requisites

- Patient and exam data are available at the scanner (either through modality worklist or manually entered at the scanner)

Main Flow

On the scanner:

- 160 1. The sonographer claims the corresponding work item and starts the corresponding exam
2. The sonographer performs some of the following steps in the site specific order
 - optimizes settings and performs 2D acquisition of anatomy/morphology of interest using one or more of the following techniques:
 - B-Mode
 - B-Mode with color flow
 - 165 • M-Mode
 - CW
 - PW
 - ...
 - optimizes settings and performs a volume acquisition of the aortic valve using one or more of the following techniques:
 - B-Mode
 - B-Mode with color flow
 - ...

(ECG signals are recorded synchronized with the volume acquisition)
- 170 3. The sonographer performs measurements during data acquisition
- 175 4. The system stores images and measurements locally. For volume data the ECG is stored in a separate object and linked to the volume
5. The sonographer reviews the acquired objects, performs additional measurements and manipulates volume data:
 - 180 • performs 3D quantification use case (see section 2.2.1)
 - performs visualization of valvular anatomy use case (see section 2.2.2)
6. The systems stores all additional images, derived views, measurements locally
7. The sonographer ends the exam
- 185 8. The sonographer either sends the study manually to PACS or the system automatically forwards the study to the PACS.

At the workplace:

1. The cardiologist (or system automatically) initiates retrieval of study from PACS (optionally a relevant previous study may be retrieved as well)
2. The cardiologist opens the study
- 190 3. The system displays all 2D images and derived views (represented in a presentation state object) on the screen.
4. The cardiologist reviews the images, views and measurements done by the sonographer on the scanner and optionally compares the results to the previous study:
 - performs 2D review (as usual)
 - 195 • reviews results from 3D quantification use case and potentially re-does the use case after adjusting views
 - performs additional visualizations of aortic valve as defined in the visualization of valvular anatomy use case (see section 2.2.2)

- 200
5. The cardiologist / system stores all additional images, derived views, and measurements locally
 6. The cardiologist switches to a summary screen and reviews measurements and adds some observations.
 7. The cardiologist either sends additional images/views/measurements manually to PACS or the system automatically forwards the study to the PACS.

205

 8. The cardiologist ends the exam

Post Conditions

- All diagnostically relevant information has been acquired and stored and is available for final reporting in the image manager.

210

Alternate Flows

- Volume data are directly sent to the workplace, where post processing and review is performed. As a result of this review process, representative 2D views are stored (as standard Ultrasound objects) and sent to the Image Manager for archival
 - At the scanner, the reviewing sonographer generates representative 2D views (as standard Ultrasound objects), which are sent to the archive. At the workplace the reading physician is reviewing the images as a 2D study.
- 215

Conclusion

In order to allow for storage, exchange and review of volume data sets from each of the scanners, image data (especially volume data and associated waveforms) and presentation states need to be stored in a standardized, vendor neutral format. Furthermore presentation states are essential for the cardiologist to see the views generated by the sonographer and to further manipulate them.

220

2.1.2 3D Echo Image exchange via Media

Description

225 This use case describes the workflow for reviewing data sets acquired at a different facility and copied to CD.

Scenario

Dr. Winter diagnosed a severe Aortic Stenosis for Tony Smith which requires surgery. He refers Tony to a cardiac surgeon for valve replacement surgery. The cardiologist asks one of the assistants to burn a CD with all images, presentation states and associated waveforms that have been acquired for Tony. When Tony arrives at the cardiac surgery unit he presents the CD to the surgeon, who opens it at his local workstation from vendor B. He opens some of the volume rendered views of the aortic valve and further manipulates it to plan surgery.

230

Pre Requisites

- 235
- Study has been burned in a standardized, vendor neutral format to media

Main Flow

At the review workstation

1. The user inserts the CD and imports the study to his local system
[Note: this could be done by following the IHE import reconciliation workflow]
- 240 2. The user opens the study and selects a volume data set depicting the aortic valve.
3. The user follows the steps defined in the use case for valve visualization below (see section 2.2.2)

Post Conditions

245 The cardiologist was able to review the CD and the included study done at a different vendor's system and using a different IT infrastructure.

Alternate Flows

- Instead of importing the study the user opens it directly from the CD. In this case no additional views/measurements could be added to the study
- 250 • Depending on the exam type or question, the user may perform any of the review use cases below.

Conclusion

255 In order to allow for review and further manipulation of volume data sets on the CD, they need to be stored in a standardized, vendor neutral format. Furthermore presentation states are essential for the cardiac surgeon to see the views generated by the cardiologist and to further manipulate them.

2.2 Review/Display use cases

2.2.1 3D quantification

Description

260 It is proven that 3D quantification of the cardiac chambers is more accurate and reproducible for multiple reasons:

- No geometric modeling is necessary
- Improved endocardial visualization

Parameters to be quantified:

- 265 • LV ejection fraction
- LV mass
- LA and RA volume
- RV volume

Scenario:

270 This use case provides some additional details to the general workflow use cases as they were
described in Section 2.1. In the scenario of Tony Smith, who is examined at Dr. Winter’s Echo
lab because of Aortic Regurgitation a quantification of the left ventricle is performed. The
sonographer at the scanner generates some representative views, which she uses in order to
perform the quantification. She stores the results (measurement information and representative
275 views) together with the images to the PACS, so that the reading cardiologist can later on
retrieve the study at the workstation and review the quantification results as part of his diagnostic
process.

Pre-Requisites

- Volume data-set(s) suitable for the quantification of the chamber in question have been captured

280 Main Flow

On the scanner (initial review by sonographer):

For each chamber, the user wants to perform quantification on

1. The user opens the volume best depicting the chamber to be analyzed (e.g. the left ventricle)
- 285 2. The system displays the volume and the associated ECG waveform time synchronized
3. The user generates view(s) appropriate to initiate the quantification algorithm and stores them:
 - adjust rotation, zoom, pan, cropping parameters
 - adjust contrast and brightness settings
 - 290 • select representative heartbeat (select start and end frame)
4. The user starts the quantification algorithm
5. The system segments the cavity and calculates relevant parameters and displays the results in one or multiple of the following options:
 - measurement values in the reporting/measurement package
 - 295 • MPR views, with outlines of segmented chamber
 - Rendered view of chamber with or without surrounding tissue
 - 16/17 segment model as rendered view
6. Optionally the user corrects segmentation results, and re-initiates quantification
7. The user annotates the images and derived views
- 300 8. The user/system stores the results and representative views (as presentation states)
9. Optionally the user generates different standard views, stores them and then performs standard 2D measurements (that were not previously calculated) on them.

At the review workstation (follow up review by cardiologist)

305 For each chamber of interest (e.g. the left ventricle), that was previously analyzed:

1. The user opens the volume through one of the representative views (presentation state) generated previously (e.g. MPRs with outlines)
2. The system displays the view of the volume and the associated ECG waveform time synchronized
- 310 3. The user reviews the results of previous analysis

- 315
4. Optionally the user corrects segmented contours and re-initiates quantification
 5. The user/system stores the updated views and quantification results as a presentation state/DICOM SR
 6. The user opens the volume through derived 2D views and reviews 2D measurement results
 7. Optionally the user modifies some of the views and re-measures
 8. The user stores any additional views/measurements (presentation state/SR) if needed.
 9. The user continues with another chamber following the previous steps

Post Conditions

- 320
- All relevant quantification results and modified views have been locally stored

Alternate Flows

- 325
- The user at the scanner does not store presentations states but rather calibrated 2D images (static/clips) or secondary capture images. These could be reviewed by the cardiologist at the review station, however further volume manipulations would not be possible. Since the data are calibrated, standard 2D measurements could be performed

Presentation State Requirements

- 330
- MPR views with calibration information
 - MPR views with segmented outlines overlaid
 - Volume rendered views of segmented chamber (or color coded display of segmented structures like wall segments) (with or without surrounding tissue)
[Note : Surface Rendering might be sufficient here as well]
 - Derived views have to reference external ECG waveform or at least the display needs to be able to open them based on the reference in the volume object

2.2.2 Visualization and analysis of valvular anatomy

335 Description

This use case defines the workflow for examining valvular heart diseases based on 3D/4D Echocardiograms, which allow better analysis of valve defects. By acquiring a volume and deriving different views of the valve and the surrounding chambers, the following advantages are evident:

- 340
- quantification of the mitral annulus
 - visualization of mitral leaflets, commissures and orifice
 - perpendicular en-face views, which enable accurate valve area measurements
 - support of surgical planning and follow up after surgery
 - more accurate quantification of mitral and aortic stenosis
- 345
- 3D color flow imaging combined with grayscale data for analysis of jets (origin, direction, orifice areas, flow measurements ...)

Scenario:

350 This use case provides some additional details to the general workflow use cases as they were described in Section 2.1. In the scenario of Tony Smith, who is examined at Dr. Winter’s Echo lab because of Aortic Regurgitation, a visualization and analysis of the morphology of the aortic valve is performed. The sonographer at the scanner generates various 3D views of the valvular anatomy including perpendicular en-face views with and without color. She stores the results together with the images to the PACS, so that the reading cardiologist can later on retrieve the study at the workstation and review the quantification results as part of his diagnostic process.

Pre-Requisites

- Volume data-set(s) suitable for valve analysis have been captured

Main Flow

On the scanner (initial review by sonographer):

- 360 For each valve to be analyzed, the user performs the following steps
1. The user opens the volume best depicting the valve to be analyzed
 2. The system displays the volume and the associated ECG waveform time synchronized
 3. The user generates different views of the valve in order to examine the valve:
 - 365 • Volume rendered views to depict the annulus, the leaflets, commissures and the orifice
 - Volume rendered views displaying color flow through the valve to evaluate jets
 - MPR views for calculating the orifice area
 - MPR views with color doppler information to measure the vena contracta, calculate the regurgitation volume through PISA
 - 370 4. The user performs an analysis of left/right ventricular function (see 3D quantification use case)
 5. The user opens CW images and performs some measurements (pressure gradients, ...)
 6. The user/system stores results and representative views (as presentation states)

375 *At the review workstation (follow up review by cardiologist)*

For each valve to be analyzed:

1. The user opens the volume through one of the volume rendered views
2. The system displays the view of the volume and the associated ECG waveform time synchronized
- 380 3. The user reviews the views and continues to manipulate them by:
 - rotating the image
 - changing rendering parameters
 - annotating the images
 - turning color on and off
- 385 4. The user saves modified views as necessary
5. The user continues with step 1 for the next view
6. The user opens an MPR view
7. The system displays the view and the associated ECG waveform time synchronized

- 390 8. The user reviews the image and the measurements and optionally changes the view for further measurements by:
- rotating the view
 - annotating the image
 - turning color on and off
 - performing further measurements
- 395 9. The user saves any modified views and analysis results as necessary
10. Optionally the user generates an animation showing the valve from different view points, turning color on and off and changing rendering parameters.
11. The user continues with step 6 for the next view

Post Conditions

- 400 • All relevant images have been reviewed and necessary measurements (based on 2D images as well as based on volume data) have been performed and stored locally

Alternate Flows

- 405 • The user at the scanner does not store presentations states but rather calibrated 2D images (static/clips) or secondary capture images. These could be reviewed by the cardiologist at the review station, however further volume manipulations would not be possible. Since the data are calibrated, standard 2D measurements could be performed.

Presentation State Requirements

- Support for volume rendered images
- Support for annotations, rendered as part of the scene or rendered as overlay

410 • Rendering of tissue data combined with color flow information

- Option to turn color on and off in volume rendered views as well as in MPRs
- Support for storing animations while changing:
 - Geometric parameters of the view
 - Rendering parameters

415 ○ Color (on/off)

 - Zoom, crop and pan
- MPR requirements as described in previous use case

2.2.3 Visualization and analysis of congenital heart defects

Description

420 This use case describes the review of volume data sets to examine congenital heart defects. Major advantages in using volumes for evaluating congenital heart disease are:

- Visualization of complex cardiac anatomy of congenital defects

- perpendicular en face view of septal defects for determining size

Scenario

425 Peter Miller, a 2 month old baby is presented at the pediatrician because of a bluish tint to the skin, fast breathing, a rapid heart rate and swelling of the legs. Since the pediatrician also hears a murmur, he refers the baby to Dr. Winter's Echo lab for an echocardiogram. Following the general workflow described in Section 2.1 the sonographer additionally generates some views of the ventricular septum and performs some quantification of the right ventricle (as defined in the
430 3D quantification use case).

Pre-Requisites

- Volume data-set(s) suitable for visualizing congenital defects and analysis have been captured

Main Flow

435 *On the scanner (initial review by sonographer):*

1. The user opens a volume.
2. The system displays the volume and the associated ECG waveform time synchronized
3. The user generates different views of the defect:
 - Volume rendered en-face perpendicular views of the ventricular septum
 - 440 • Volume rendered views displaying color flow through the VSD to evaluate shunt
 - MPR views for calculating the size of the opening
4. The user performs the 3D quantification use case for the right ventricle
5. The user/system stores results and representative views (as presentation states)

445 *At the review workstation (follow up review by cardiologist)*

For each valve to be analyzed:

1. The user opens the volume through one of the volume rendered views
2. The system displays the view of the volume and the associated ECG waveform time synchronized
- 450 3. The user reviews the view and continues to manipulate it by:
 - rotating the image
 - changing rendering parameters
 - annotating the images
 - turning color on and off
- 455 4. The user saves modified views as necessary
5. The user continues with step 1 for the next view
6. The user opens an MPR view
7. The system displays the view and the associated ECG waveform time synchronized
- 460 8. The user reviews the image and the measurements and optionally changes the view for further measurements by:
 - rotating the view
 - annotating the image
 - turning color on and off

- performing further measurements
- 465 9. The user saves any modified views as necessary
10. The user continues with step 6 for the next view

Post Conditions

- All relevant images have been reviewed and necessary measurements (based on 2D images as well as based on volume data) have been performed and stored locally. Additional derived views have been stored locally.
- 470

Alternate Flows

- The user at the scanner does not store presentations states but rather calibrated 2D images (static/clips) or secondary capture images. These could be reviewed by the cardiologist at the review station, however further volume manipulations would not be possible. Since the data are calibrated, standard 2D measurements could be performed.
- 475

Presentation State Requirements

- Support for volume rendered images
 - Support for annotations, rendered as part of the scene or rendered as overlay
 - Rendering of tissue data combined with color flow information
 - Option to turn color on and off in volume rendered views as well as in MPRs
 - MPR requirements as described in previous use case
- 480

2.2.4 3D Fetal Echocardiography

Description

485 Acquiring the correct views for evaluating fetal cardiac anatomy is not an easy process. Through acquiring a volume dataset of the fetal heart and extracting the standard views normally used for fetal screening the process could be significantly simplified. The following default views could be derived from the volume for further analysis:

- 4-chamber view
 - Outflow tract
- 490

Further advantages are in the use of volume rendered views from the outside of the heart in order to depict the complex cardiac anatomy especially in heart defects affecting the outflow tract and any abnormalities of great artery relationship.

Scenario

495 Amy Myers, pregnant for 20 weeks, gets a referral for a fetal echocardiogram due to an increased risk for congenital heart disease because of family history of congenital heart disease. The overall workflow steps are defined as in Section 2.1. The sonographer acquires one or multiple volume datasets and generates diagnostic views which are needed for evaluation.

Pre-Requisites

- 500 • A B-Mode volume data-set and suitable B-Color volume(s) have been acquired.

Main Flow

On the scanner:

1. The user selects a B-Mode volume dataset best depicting the heart and opens it.
2. System loads the volume dataset and displays it.
- 505 3. The user manipulates the volume to generate a MPR of the four chamber view (rotate, zoom and crop as well as contrast manipulations).
4. The user stores the image locally.
5. The user performs measurements and analysis of the four chamber view.
6. The system stores the measurement results locally
- 510 7. If color flow information was present in the in the image the user turns color on and optimizes display.
8. The user stores the derived view locally
9. The user continues to manipulate the volume to obtain relevant views of the outflow tract (5 chamber view, three vessel view and tracheal view) and performs measurement on
- 515 derived views.
10. The user stores the additional views and measurement information locally.
11. If color flow information was present in the in the image the user turns color on and optimizes display.
12. The user stores the derived view locally.
- 520 13. The user generates volume rendered views of the outside of the heart, especially displaying the outflow tract and the major arteries.
14. The user stores these derived views locally.

At the review workstation (follow up review by cardiologist)

For each derived view to be reviewed

- 525 1. The user opens the derived view
2. The system displays the view
3. The user continues to manipulate the view, until he is satisfied:
 - Rotate
 - Zoom
 - 530 • Crop
 - Contrast enhancements
 - Rendering parameters
4. The user reviews measurements and eventually adds some more measurements or corrects some of the existing measurements
- 535 5. The user stores any updated views and measurements locally on the system

Post Conditions

- 540
- All relevant images have been reviewed and necessary measurements (based on 2D images as well as based on volume data) have been performed and stored locally. Additional derived views have been stored locally.

Alternate Flows

- 545
- The user at the scanner does not store presentations states but rather calibrated 2D images (static/clips) or secondary capture images. These could be reviewed by the cardiologist at the review station, however further volume manipulations would not be possible. Since the data are calibrated, standard 2D measurements could be performed.

2.2.5 Volume Stress Echo

Description

Volume Stress Echocardiography has the potential to overcome some of the limitations in 2D Stress Echocardiography such as:

- 550
- Insufficient visualization of the left ventricle
 - Difficulties in positioning the probe resulting in inadequate imaging planes
 - Time consuming serial acquisitions during the narrow window of peak stress.

This use case should cover fast volume acquisition at different stress levels, and wall motion analysis based on MPRs of standard views.

Scenario

555 John Walters is referred to Dr. Winter's Echo Lab with suspected CAD for a stress echo test. The sonographer performs the acquisition of volume data for each stage, selects appropriate volumes and generates standard views for wall motion scoring. Dr. Winters, after retrieving the study at the workstation, re-adjust some of the views, selects representative heart beats and
560 performs wall motion analysis as well as some LV quantification (as described in the 3D quantification use case)

Pre-Requisites

- Patient has been registered (either through modality worklist or manually at the scanner)

Main Flow

565 *At the Scanner*

1. The sonographer prepares patient
2. The sonographer selects/registers the patient and start the Stress Echo exam
3. The sonographer starts image acquisition and acquires one or more volumes in the resting stage
- 570 4. The system stores the acquired data sets locally (marked as resting stage)
5. Patient exercises/stress agents are administered
6. For each stress stage:

- 575
- a. The sonographer captures one or more volumes for that stage
 - b. The system stores the acquired data sets locally (marked with the appropriate stage information)
7. The sonographer reviews the stress data sets:
- a. The user selects appropriate volume(s) for each stage
 - b. The user (or system automatically) generates standard 2D views for wall motion analysis (A4C, A3C, A2C, and short axis views on various levels), and optionally selects representative heartbeats for each view and then saves them locally as presentation states.
- 580
8. The sonographer ends the study
 9. The sonographer either sends the study manually to the PACS or the system automatically forwards it to the PACS.

585 *At the workstation*

1. The cardiologist or system initiates retrieval of the study from the PACS
 2. The cardiologist opens the study
 3. The system displays the study for stress review (depending on user preferences, either sorted by stage or by view). Each view displayed is synchronized with the ECG associated with the respective volume data set
- 590
4. The cardiologist reviews the study, eventually corrects some of the derived views and saves them. The corrections might include things such as:
 - changing the orientation to better depict wall segments
 - selecting a representative heart beat
- 595
- cropping, zooming and panning to better visualize a region of interest
5. The cardiologist performs wall motion analysis.
 6. The cardiologist performs some quantification on the MPR views or performs the 3D quantification use case on selected volumes.
 7. The system stores analysis results locally

600 **Post Conditions**

- Wall motion analysis and quantification results and (optionally) modified views have been stored locally.

Alternate Flows

- 605
- Rather than saving presentation states at the scanner the user stores the derived views as standard DICOM ultrasound multi-frame objects with calibration information. Wall motion

analysis could be performed based on these 2D objects, however further volume manipulation/view correction would not be possible.

2.2.6 Tissue Doppler Imaging Use Case

610 Scenario

Steven Goldstein, a 55 year old patient suffering from congestive heart failure (CHF) underwent cardiac re-synchronization therapy (CRT) recently. He comes to Dr. Winter's Echo Lab for a follow up exam.

615 Following the general workflow defined in Section 2.1 the sonographer performs the image acquisition (including Tissue Doppler Images) and an initial analysis at the scanner. Later on Dr. Winter retrieves the study from his PACS together with Steve's study prior to CRT to analyze the outcome of the therapy.

Pre-Requisites

- 620 • A B-Mode volume data-set and a suitable Tissue Doppler volume dataset have been acquired.

Main Flow

On the scanner (initial review by sonographer):

1. The sonographer opens the Tissue Doppler volume data set.
2. The system displays the volume and the associated ECG waveform time synchronized
- 625 3. The sonographer manipulates the volume (rotates, zooms, crops)
4. The sonographer stores those MPR views locally as a presentation state.
5. The sonographer performs an initial analysis of the derived views and stores the results.
6. The sonographer selects a B-Mode volume dataset and performs the 3D quantification use case for the left ventricle.

630

At the review workstation (follow up review by cardiologist)

For each view to be analyzed:

1. The cardiologist opens the current and prior volume through one of the derived views
2. The system displays the views from the current and the prior study and the derived results
- 635 3. The user reviews the views and continues to manipulate them by:
 - rotating the image
 - annotating the images
 - turning color on and off
- 640 4. The user saves any modified views as necessary
5. The user performs analysis of the data sets
6. The user continues with step 1 for the next view

645 **Alternate Flow**

- Rather than saving presentation states at the scanner the user stores the derived views as standard DICOM ultrasound multi-frame objects with calibration information. Analysis could be performed based on these 2D objects, however further volume manipulation/view correction would not be possible.

650 **Post Conditions**

The cardiologist has compared the current and prior study, performed analysis and stored representative views.

2.3 Use cases for future consideration

655 3D Echocardiography is still a relatively new technology and is not yet in widespread clinical use. With further use, new imaging applications and protocols will evolve. Areas that are of interest include:

- Fusion of 3D echocardiography data sets with CT data for better assessment of the morphology
- Fusion of 3D echocardiography data sets with EP lab data to overlay the
660 electrophysiology information on top of the Echo data.

3 Technical Requirements /Pre-Requisites from DICOM

3.1 nD Presentation State requirements

1. Support for Multi Planar Reconstruction with parameters like
 - 665
 - Plane Origin vector
 - Row and Colum Vector (vectors to define orientation of the MPR)
 - Slice Thickness
 - Support for the blending pipeline as defined in the Enhanced Ultrasound Volume IOD (PS 3.3-2009 C.7.6.23)
 - 670
 - Annotations (e.g. outlines of segmented structures or other calculated values like long axis, measurement primitives drawn on image, textual annotations)
 - Cropping parameters
 - Zoom and pan
2. MPRs shall contain
 - 675
 - Calibration information in order to allow for measurements
 - View labels to allow stress review (View Code Sequence)
 - [Note: is the stage information from the original volume sufficient or do we need to add stage code sequence for volume stress use case?]
3. Support for rendered views with parameters like
 - 680
 - Camera position and viewing direction
 - Rendering algorithm: volume rendering/surface rendering/...
 - Shading/lighting parameters
 - Color mapping for segmented structures
 - Blending information as defined in the Enhanced Ultrasound Volume IOD (PS 3.3-2009
 - 685 C.7.6.23)
 - Rendering of sub-volumes
 - Zoom and pan
 - Annotations inside the rendered view
4. Visualization of segmented structures (e.g. like LV or wall segments) by surface rendering
 - 690
 - Color coded display of segmented structure on its own
 - Color coded display of segmented structure with surrounding tissue
5. Display of rendered views/presentation states synchronized with external waveforms
6. Support for animated scenes
 - 695
 - Changes in camera position and viewing direction (e.g. slicing through the heart or rotation around a valve to see the valve from different points of view)
 - Changes in color display
 - Changes in lighting parameters

7. Time limit volume clips

- 700
- Applies to both, MPR views as well as volume rendered views.
 - Select start and end frame.
Note: How would that work with the associated waveforms and the time synchronized display?

3.2 Structured Report Requirements

- 705
1. Codes for volume based calculations methods need to be added to Echocardiography Volume Method (CID 12228)
 2. Adding Codes for specific 3D measurements

4 Proposal for the 3D/4D Echo Supplement

710 There are two different options to define a supplement for 3D/4D Echo workflow:

1. Develop a content profile modeled after the PERF/DIFF profiles defined by IHE Radiology. This approach would address the workflow between an acquisition modality, the image manager/archive, image display and evidence creator (see Figure 4.1).

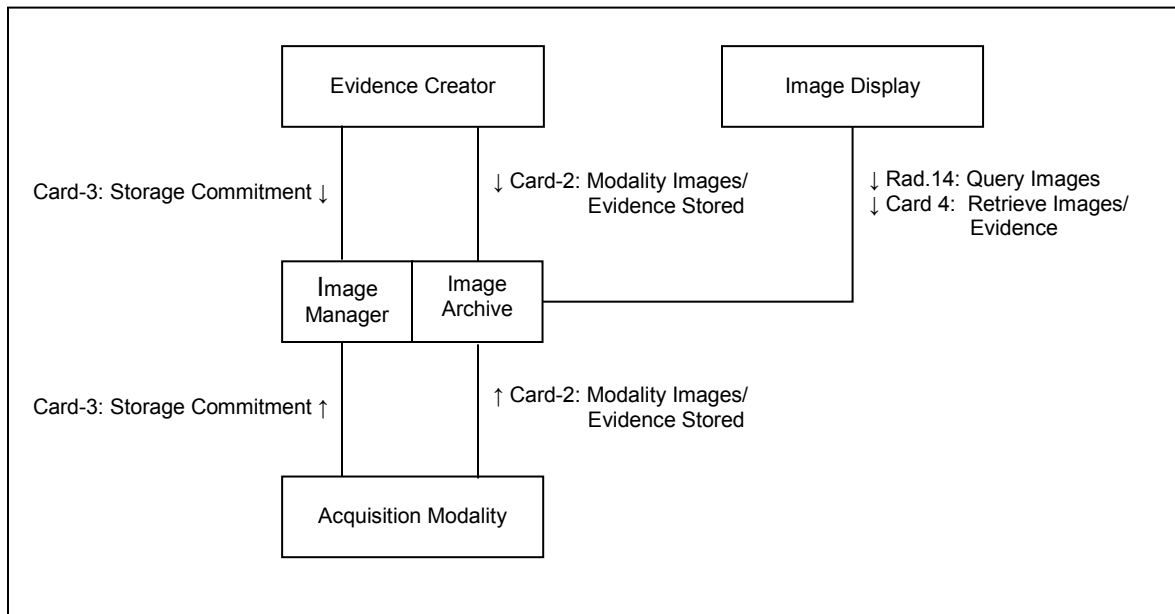
715 In this scenario updates to the Card-2 (Modality Images/Evidence stored) and Card-4 (Retrieve Images/Evidence) transactions would be necessary in order to address support for storage of the additional SOP Classes, potentially transfer syntaxes, and for the new Pediatric Echo SR template (TID 5300).

- Enhanced Ultrasound Volume Storage SOP Class
- General ECG Waveform Storage SOP Class
- 720 • Arterial Pulse Waveform Storage SOP Class
- Respiratory Waveform Storage SOP Class
- General Audio Waveform Storage SOP Class
- nD Presentation State

725 In addition to supporting some more SOP Classes, there might be some extensions to the existing Echo templates (TID 5200 and 5300 and underlying context id) necessary, to allow for the storage of 3D measurement data.

The extension to the Card-4 transaction would have to address specific requirements for the display of volume data:

- Handling of multiple series, dealing with different frames of reference
- 730 • Synchronized display external waveform and volume data
- Display of volume data based on presentation state objects
- Support for the Blending Pipeline as defined in the Enhanced US IOD



735

Figure 4-1: Actor/Transaction Diagram proposal for 3D Echo Workflow

2. Rather than defining a new profile, support for the 3D Echocardiography images could be added as an option to the existing Echocardiography Workflow profile. This would affect the actors Acquisition Modality, Image Manager/Archive, Image Display and Evidence Creator. The Card-2 and Card-4 transactions would have to be extended with the same functionality as stated in the first solution.

740

Implementation wise both options would require the same amount of work, since the same requirements have to be fulfilled. The decision, which option to choose should be based on general discussions within the cardiology domain, on how to handle content profiles.

745